

PEDIATRICS®

OFFICIAL JOURNAL OF THE AMERICAN ACADEMY OF PEDIATRICS

Findings in Older Children With Abusive Head Injury: Does Shaken-Child Syndrome Exist?

Hani Salehi-Had, James D. Brandt, Angela J. Rosas and Kristen K. Rogers

Pediatrics 2006;117:e1039-e1044

DOI: 10.1542/peds.2005-0811

The online version of this article, along with updated information and services, is located on the World Wide Web at:

<http://www.pediatrics.org/cgi/content/full/117/5/e1039>

PEDIATRICS is the official journal of the American Academy of Pediatrics. A monthly publication, it has been published continuously since 1948. PEDIATRICS is owned, published, and trademarked by the American Academy of Pediatrics, 141 Northwest Point Boulevard, Elk Grove Village, Illinois, 60007. Copyright © 2006 by the American Academy of Pediatrics. All rights reserved. Print ISSN: 0031-4005. Online ISSN: 1098-4275.

American Academy of Pediatrics

DEDICATED TO THE HEALTH OF ALL CHILDREN™



Findings in Older Children With Abusive Head Injury: Does Shaken-Child Syndrome Exist?

Hani Salehi-Had, BA^a, James D. Brandt, MD^a, Angela J. Rosas, MD^b, Kristen K. Rogers, PhD^b

^aDepartment of Ophthalmology, University of California Davis Medical Center, Sacramento, California; ^bDepartment of Pediatrics, Child and Adolescent Abuse Resource and Evaluation Diagnostic and Treatment Center, University of California Davis Children's Hospital, Sacramento, California

The authors have indicated they have no financial relationships relevant to this article to disclose.

ABSTRACT

Shaken-baby syndrome (SBS) has been hypothesized to occur after shaking by an adult during the first 2 years of life. We wondered whether it is possible to achieve rotational forces sufficient to cause SBS-like injuries in children >2 years of age. The present study describes cases of child abuse in older children who presented with the classic ophthalmologic and intracranial findings of SBS. In this case series, 4 cases of older children (2.5–7 years old; 11.8–22 kg) who died from abusive head injuries and who had diffuse retinal hemorrhages identified antemortem were selected for review. The cases were abstracted from hospital charts, records from autopsies, coroners' and district attorneys' offices, and court transcripts. In all 4 cases the history provided by the primary caregiver did not match the severity of the injuries. Three case subjects presented with patterned bruises. Multilayered retinal hemorrhages and acute subdural hematoma were observed in all 4 cases. At autopsy, diffuse axonal injury was evident in 3 of the 4 cases; all 4 cases had optic nerve sheath hemorrhages. None of the victims had skeletal fractures on radiologic examination or at autopsy. This case series demonstrates that it is possible to observe SBS-like retinal and central nervous system findings in the older and heavier child. Our findings underscore the need for providers to consider intentional shaking as a mechanism of injury in the evaluation of abusive head injury in older children.

CHILD ABUSE IS a significant cause of morbidity and mortality in the pediatric population. In 2002, child protection agencies across the United States investigated >3 million cases of child abuse and >29% of the children evaluated were found to be victims of abuse.¹ In the same year, an estimated 1400 children died as a result of abuse or neglect.¹ Abusive head injury accounts for up to 80% of fatalities and is the leading cause of death among children as a result of child abuse.^{2,3} In 2002, child abuse homicide was the second leading cause of injury death among infants in the United States, and the third leading cause among 1- to 4-year-olds.⁴ Underreporting and misdiagnosis remain a major problem; it is believed that up to 85% of deaths resulting from abuse are attributed to some other cause on death certificates.⁵

In 1974, John Caffey introduced the idea that vigorous shaking by a caregiver can result in serious and even fatal head injury. He termed this condition "whiplash shaken-infant syndrome."⁶ Since then the syndrome has been renamed "shaken-baby syndrome" (SBS) and redefined as a condition of multiorgan injuries sustained by the violent shaking of an infant or small child. The classic findings in SBS may include bilateral multilayered

retinal hemorrhages, acute subdural hematoma, cerebral edema, posterior rib fractures, and metaphyseal fractures.

Head trauma in small children resulting from shaking injury is associated with a much worse neurologic outcome than direct blunt head trauma.^{7–9} This is thought to be due to the difference in the mechanism of injury. Violent shaking of the subject causes severe rotational acceleration and deceleration forces on the brain, which results in shearing injury to the white matter causing diffuse axonal injury and, occasionally, cerebral edema,

Key Words: shaken-baby syndrome, child abuse, retinal hemorrhages

Abbreviations: SBS, shaken-baby syndrome; CT, computed tomography; CAARE, Child and Adolescent Abuse Resource and Evaluation; UCDC, University of California Davis Children's Hospital; GCS, Glasgow Coma Scale

www.pediatrics.org/cgi/doi/10.1542/peds.2005-0811

doi:10.1542/peds.2005-0811

Accepted for publication Nov 7, 2005

Address correspondence to Kristen K. Rogers, PhD, Department of Pediatrics, CAARE Diagnostic and Treatment Center, University of California Davis, 3300 Stockton Blvd, Sacramento, CA 95820. E-mail: kristen.rogers@ucdmc.ucdavis.edu
PEDIATRICS (ISSN Numbers: Print, 0031-4005; Online, 1098-4275). Copyright © 2006 by the American Academy of Pediatrics

as well as tearing of the bridging veins, which gives rise to subdural hemorrhages.^{10,11}

Similarly, shearing force on the retinal vessels causes the pattern of retinal hemorrhages observed in SBS. Diffuse retinal hemorrhages are seen in 70% to 85% of children with nonaccidental head trauma involving vigorous shaking.^{12–14} In association with retinoschisis or subdural hematomas, retinal hemorrhages are strongly suggestive of shaking as the underlying mechanism of injury.^{13,15,16} Although the differential diagnosis of retinal hemorrhages in young children is broad, in the absence of hematologic abnormalities retinal hemorrhages in the first 2 years of life are predominantly documented in cases of shaken abuse. Although there are reported cases of retinal hemorrhages, including multilayered hemorrhages, as evidenced in children post-motor vehicle accident, most studies have reported no retinal hemorrhages in noninflicted neurotrauma or after severe, witnessed noninflicted blunt trauma.^{10,15,17–21} However, the pattern of the retinal hemorrhages described in the documented cases of severe noninflicted neurotrauma is different from those observed in SBS.^{17,22} Noninflicted retinal hemorrhages are isolated to the posterior pole with no peripheral involvement, are not observed in all retinal layers, and are not associated with retinoschisis.¹⁷ Thus, documentation of diffuse multilayered retinal hemorrhages with or without the presence of retinoschisis is strongly suggestive of SBS.

SBS is often interchangeably referred to as “shaken-infant syndrome” and is most commonly documented in children <2 years of age. Beyond a few individual case reports of retinal hemorrhages in older children,^{23–25} documentation of SBS in children >2 years of age has been rare. Infants are believed to be particularly susceptible to SBS because of their relatively large and heavy head, undeveloped neck muscles, and small size, allowing for substantial rotational shearing forces to be generated by shaking the child while holding the child about the chest. In 1997, Pounder²⁶ reported the first case of shaken-adult syndrome with bilateral retinal hemorrhage, subdural hematoma, and diffuse axonal injury in a 30-year-old male who was repeatedly shaken under interrogation. A second case report of shaken-adult syndrome in a domestic violence case was documented in 2000.²⁷ The patient had injuries associated with SBS: retinal hemorrhages, subdural hematoma, and patterned bruising. Both of these case reports leave open the possibility that an SBS-like syndrome might occur in older children and adults; if true, shaking provides a plausible mechanism to partly account for the high morbidity and mortality of abusive head injury in the older pediatric population.

METHODS

The University of California Davis Medical Center (UCDMC) houses the Children’s Hospital (UCDCH), which is

a level 1 pediatric trauma center, serving all of northern California. UCDCH is also home to the Child and Adolescent Abuse Resource and Evaluation (CAARE) Diagnostic and Treatment Center, a multidisciplinary clinical program evaluating and treating >2000 cases of suspected child abuse annually. This case series comprises a convenience sample of 4 subjects identified by the authors from records at the CAARE Center that presented to UCDCH between 1993 and 2002, were >2 years of age at the time of admission, had retinal hemorrhages identified antemortem, and died as a result of closed head injury due to confirmed (through postmortem examination and subsequent convictions of their respective abusers) physical abuse. A multidisciplinary team at the UCDMC, consisting of a pediatric intensive care specialist, pediatric child abuse specialist (from UCDCH), pediatric radiologist, ophthalmologist experienced in the examination of children with traumatic brain injury, and a pathologist, was involved in the assessment and diagnosis of each case presented here. Institutional review board approval was obtained from the UCD School of Medicine. Case information was abstracted from hospital charts, radiologic studies, autopsy reports, records from the relevant coroner’s and district attorney’s offices, and court transcripts.

Case Reports

Case 1

A 7-year-old, 18.6-kg (4th percentile for weight by age) boy was transported by ambulance from home to UCDCH. The stepfather and mother of the child initially reported that the child had been discovered in bed gurgling and unresponsive. Later the stepfather stated he had heard a “thud” and went to the child’s room, where he found the child on the floor near some furniture, gurgling and unresponsive. The mother denied any domestic violence or abuse by the stepfather. Additional history obtained at UCDCH was significant for a previous admission to an outside hospital for a “fall from a 6-foot fence” 10 days before presentation. At that admission the child was observed for 4 days for a splenic laceration and was discharged from the hospital.

On arrival to UCDCH the child was intubated and comatose with dilated and fixed pupils. Numerous external injuries were noted, including patterned bruises and abrasions on both arms, genitals, lower abdomen, and inner thighs. Indirect ophthalmoscopy by the ophthalmic consultant revealed bilateral, multilayered retinal hemorrhages with evidence of retinoschisis (Fig 1). A skeletal series revealed no evidence of rib or long bone fractures. A head computed tomography (CT) scan revealed severe brain edema involving the left cerebrum and a portion of the right frontal lobe, with an underlying small acute left subdural hematoma with a 6-mm left-to-right shift, subarachnoid hemorrhage and an un-

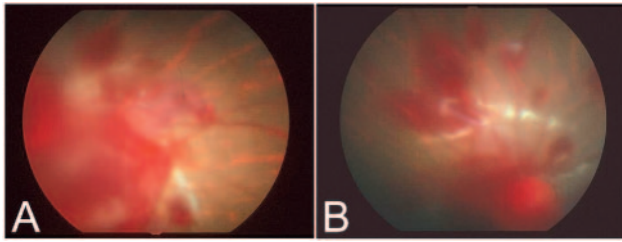


FIGURE 1
Retinal photographs from case 1. Bilateral retinal hemorrhages are observed at all levels of the retina: subretinal, intraretinal, and preretinal hemorrhages. Retinoschisis was observed in 1 eye (B).

cal and subfalcine herniation (Fig 2A). CT studies of the abdomen with contrast revealed a small splenic laceration and multiple thick-walled bowel loops in the right lower quadrant. Hematologic and coagulation studies were within normal limits. The child expired a few hours after admission.

Autopsy revealed that the age of injuries was consistent with an event that occurred around the time of the death. There was evidence of facial contusions, multiple subscapular hemorrhages, blunt force injuries of torso and extremities with multiple nondescript contusions of the back, and patterned linear contusions of the upper and lower extremities (Fig 3). There were no fractures evident on radiologic or gross musculoskeletal examination. There was evidence of hemorrhage of the small bowel mesentery and the small splenic laceration. Gross and microscopic examination of the brain revealed subarachnoid hemorrhage (Fig 2B), diffuse brain swelling, central herniation with Duret's hemorrhages in mid-brain and pons, acute anoxic/ischemic encephalopathy, and traumatic axonal injury. Gross and microscopic evaluation of both eyes revealed bilateral optic nerve sheath hemorrhage and multilayered retinal hemorrhages involving both the posterior pole and periphery.

The history provided by the stepfather, who was accused of the abuse, was inconsistent with the child's injuries throughout the course of the investigation. The

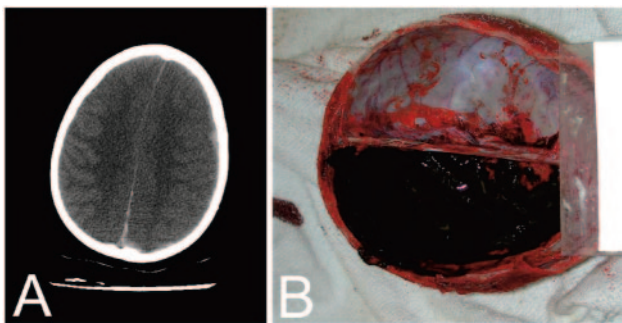


FIGURE 2
Central nervous system findings from case 1. A, CT scan demonstrating severe cerebral edema, left worse than right, with an underlying small left subdural hematoma, a 6-mm left-to-right shift, and an interhemispheric blood. B, Autopsy photograph demonstrating a subarachnoid hemorrhage.

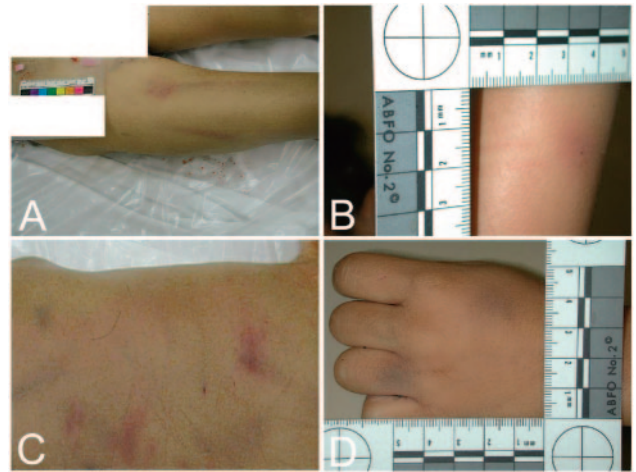


FIGURE 3
Evidence at autopsy (case 1) of multiple bruises and abrasions. A, Linear patterned bruises of the right thigh; B, patterned linear contusions of the right arm; C, multiple nondescript contusions of the back; D, bruises of the left hand.

perpetrator pled not guilty, denied any culpability, and was subsequently convicted on 2 counts: murder and child abuse with death.

Case 2

A 3-year-old male weighing 14.1 kg (42nd percentile) who lived with his mother, 8-year-old brother, and the mother's boyfriend was found by his brother unconscious and unresponsive in his bed. The brother notified the mother's boyfriend, who was the only adult present. Emergency medical personnel found the child unconscious with bradycardia; after intubation and stabilization at a local hospital, he was transported to UCDC. On arrival the child was unresponsive and had a Glasgow Coma Scale (GCS) of 3. Injuries noted on admission included ecchymosis on the forehead and cheeks bilaterally, multiple small puncture wounds on the trunk and lower extremities, and multiple bruises in the back. An anal laceration was noted. Ophthalmologic consult revealed extensive bilateral retinal hemorrhages, both old and new. The rest of a complete physical examination did not show any abnormalities. A head CT scan revealed a left subdural hematoma with diffuse massive cerebral edema with significant mass effect. The results of the coagulation studies were within normal limits. His condition declined, and he was taken off life support hours after admission.

At autopsy, abrasions and multiple bruises of varying age were noted over the head, face, chest, back, and both legs. Patterned linear and circular hypopigmented scars were observed in the lower back and the posterior aspect of both lower extremities respectively. There was no radiologic or gross evidence of fractures or bony abnormalities. Focal erythema of the colonic mucosa was noted. Gross and microscopic examination of the brain revealed a left-sided subdural hematoma with transten-

torial, cerebellar tonsillar, and left subfalcine herniation. Duret's hemorrhages of the upper brainstem were present. There was evidence of diffuse axonal injury. Gross evaluation of the eyes revealed bilateral optic nerve sheath hemorrhage. Microscopic examination of the eyes was not conducted.

The mother's boyfriend denied any abuse to the child. His story was inconsistent with the facts in the case and the multiple injuries to the child. The perpetrator pled not guilty, but was convicted on 2 counts of murder and child abuse with death. The trial transcript records an eyewitness account by a neighbor's child that the defendant had "shook [the child] like a rug."

Case 3

A 2.5-year-old female child weighing 11.8 kg (18th percentile) was in the care of an adult male relative when she reportedly began shaking and gasping for air while drinking out of her bottle. The caretaker felt no pulse, initiated cardiopulmonary resuscitation, and called 911. At the local emergency department the child was unresponsive and had a GCS of 3; she was intubated and transported to UCDCH for additional evaluation. No external signs of physical trauma were observed on admission. Indirect ophthalmoscopy by the ophthalmic consultant revealed multiple focal bilateral multilayered retinal hemorrhages. Intraretinal and preretinal hemorrhages were seen primarily in the posterior poles bilaterally. A skeletal survey failed to demonstrate rib or long bone fractures. Results of hematologic studies were all within normal limits. CT and MRI of the head showed marked diffuse brain edema and herniation with brainstem compression and a subdural hematoma. The child was declared brain dead 4 days after admission.

At autopsy, no visible external trauma of the face, scalp, chest, or extremities was observed. No gross evidence of fractures or bony abnormalities was noted. Gross examination of the brain and dura revealed a left acute subdural hemorrhage, diffuse cerebral edema, and hypoxic encephalopathy with diffuse encephalomalacia. Microscopic sections of the brain provided evidence of acute diffuse axonal injury and diffuse acute cerebral ischemic damage with reperfusion hemorrhages. Gross sectioning of the eye showed few "minute" retinal hemorrhages at the posterior poles and few faint hemorrhages along the posterior vascular arcades bilaterally. No retinal detachments or subretinal hematomas were present. Bilateral moderate acute optic nerve sheath hemorrhages were noted.

The parents were not present at the time of the child's initial symptoms. They left for work early in the morning and left the care of the children to the father's adult male cousin. This relative denied any responsibility in the abuse. He was, however, immediately placed in custody while the deputy district attorney assigned to the case and his investigators worked on obtaining evidence. A

preliminary hearing occurred, and the defendant continued to plead not guilty of the crime. There was discrepancy in the timing of these injuries, which were classic SBS findings. The argument was used by the defense that the child's injuries had to have been inflicted several hours before the relative was present in the home to caretake the children. The "window of opportunity" was several hours, and the child had contact with numerous adults during this timeframe. All potential perpetrators were interviewed, and all denied culpability. In addition, there were no external injuries that may have helped with evidence or time sequencing. After 14 months, the District Attorney's Office dismissed this case on grounds of insufficient evidence. No perpetrator was ever identified.

Case 4

A 6-year-old boy weighing 22 kg (65th percentile) was found unresponsive on the wet floor of the residence bathroom after his father called 911. He was transported to the closest medical facility, where he had a GCS of 3. He was stabilized, intubated, and transported by helicopter to UCDCH. He was unresponsive, with fixed and dilated pupils. He was noted to have eyelid burns bilaterally and multiple bruises over all 4 extremities and on his trunk. Ophthalmologic consult revealed retinal hemorrhages to the periphery of the left eye and a normal ophthalmologic examination on the right eye. A head CT scan showed a small right frontotemporal subdural hematoma, massive swelling of the right hemisphere with 1-cm right-to-left shift, and effacement of the right ventricle. An abdominal CT scan showed a liver laceration, edematous gastric wall, and free fluid in Morison's pouch and adjacent to the right adrenal gland. The results of coagulation studies were normal. An exploratory laparotomy demonstrated a lacerated liver, duodenal hematoma, and retroperitoneal hematoma. A left frontal ventriculostomy was performed to monitor and control intracranial pressure. Despite aggressive medical intervention, the child expired 2 days after admission.

At autopsy multiple "train track"-patterned cutaneous contusions, patterned cutaneous abrasions of trunk, extremities, and scalp, multiple scars of varying ages on face, trunk, and extremities, and second-degree burns of bilateral upper and lower eyelids were noted. There was no evidence of skeletal fractures. Gross and microscopic examination of the brain revealed a right-sided subdural hematoma and cerebral edema with right subfalcine herniation. Diffuse acute cerebral ischemic damage was noted. Gross examination of the eye revealed bilateral retinal hemorrhage and mild optic nerve sheath hemorrhages.

The perpetrator of this abuse was the child's biological father, who denied any responsibility in the case. His recollection of the events precipitating the abuse were inconsistent with the child's physical findings. He was

brought before a jury and convicted on 2 counts: murder and child abuse with death.

RESULTS

The subjects in this case series report were between 2.5 and 7 years of age. They weighed between 11.8 and 22 kg. In all 4 cases the history provided by the family did not match the severity of the injuries, and in 1 case there was a witness to a shaking episode. On physical examination, 3 of the cases had patterned bruises and 1 had burns, all consistent with physical abuse. In case 3 there was no evidence of impact injury and external trauma. Multilayered retinal hemorrhages and acute subdural hematoma were found in all 4 cases. Retinal hemorrhages had peripheral involvement in 3 of the 4 cases. Retinoschisis was observed clinically in 1 case. At autopsy, diffuse axonal injury was evident in 3 of the 4 cases; optic nerve sheath hemorrhages were found in all 4 cases. There was an absence of bone fractures in all cases. The cause of death documented on the death certificates was multiple blunt trauma in 2 of the cases and craniocerebral trauma in the remaining 2 cases. The perpetrators were convicted of homicide in 3 of the 4 cases.

DISCUSSION

SBS has been widely documented in children <2 years of age; in much of the literature, the syndrome is described as being more or less limited to infancy. There is a paucity of data on older children with shaken-head injury and its pattern of presentation. In most cases of older children with abusive head trauma, the mechanism of injury is generally assumed to be blunt trauma. Here we present a case series of abusive head injury in children >2 years of age with retinal findings consistent with rotational acceleration/deceleration shearing forces. This case series suggests that it is possible to achieve the forces necessary to cause the pattern of ocular and central nervous system injury associated with shaking abuse in the older, heavier child.

There are notable differences in the presentation of shaking abuse in older children. In our case series and in a recently reported case of an 8-year-old with shaken abuse,²³ there is a peculiar absence of the posterior rib and metaphyseal fractures typically seen in infants with SBS. This may be because of the more developed and stronger bones of older children. Alternatively, the actual mechanics of injury may be different because the older child is heavier and the abuser may hold the victim by the shoulders or grasp them directly by the head rather than the thorax while shaking them. This would eliminate the flapping of the extremities and flexion of the rib cage that are thought to cause the extremity and rib fractures commonly seen in infants with SBS. This observed difference is also significant in guiding the clinical evaluation of suspected cases of child abuse. It em-

phasizes the point that even in the face of a negative skeletal survey, the possibility of shaken abuse should not be ruled out, especially in the older pediatric population. Finally, although patterned bruises and burns are common findings in the setting of physical abuse of older children (and were observed in 3 of our 4 cases), such patterned injuries are rare in SBS.

In 3 of our 4 cases, abusive injury would undoubtedly have been recognized as the cause of death, but in the absence of the documented retinal findings, the mechanism of injury would likely have been attributed to blunt force trauma; in the fourth child (case 3), there was no evidence of impact injury or external trauma, and the retinal findings were instrumental in identifying shaking as the likely mechanism of injury. Retinoschisis was reported in the ophthalmologic examination in 1 of 4 cases. This finding is confirmed in the antemortem clinical photograph (Fig 1B). Retinoschisis represents a splitting of the layers of the retina and is felt to be virtually pathognomonic for the shearing forces generated during violent shaking, when the strong attachments of the vitreous to the retinal surface pull and shear the retinal surface.^{16,22,28} It is notable that retinoschisis was not described on the forensic autopsy of this case. This fact, however, is not surprising because it is difficult to differentiate retinoschisis from postmortem changes and tissue-processing artifacts unless an experienced ophthalmic pathologist is involved in the processing of the eye. An ophthalmic pathologist was not involved in the autopsy of this case.

Our case series emphasizes the need to consider a shaking mechanism as the cause or part of the cause of abusive head injury even in older children. Unrecognized shaking, as an underlying mechanism of injury that can lead to diffuse axonal injury and swelling, may help explain the high morbidity and mortality of abusive head injury in the pediatric population when compared with purely accidental closed head injury.

This series suggests that in cases of closed head injury in children with severe neurologic impairment, ophthalmic findings suggestive of a shaking injury may be found, even in older children. There does not seem to be an upper age limit for the findings and grim prognosis of SBS.

ACKNOWLEDGMENT

Equipment and funding was provided by the University of California Davis Children's Hospital, Child and Adolescent Abuse Resource and Evaluation Diagnostic and Treatment Center and Medical Center.

REFERENCES

1. US Department of Health and Human Services Administration for Children Youth and Families. *Child Maltreatment 2002*. Washington, DC: US Government Printing Office; 2004

2. DiMaio V, DiMaio D. *Forensic Pathology*. Vol 27. 2nd ed. Boca Raton, FL: CRC Press; 2001:592
3. Alexander R, Levitt C, Smith W. Abusive head trauma. In: Reece R, Ludwig S, eds. *Child Abuse: Medical Management and Diagnosis*. Philadelphia, PA: Lippincott Williams & Wilkins; 2001:47–80
4. Centers for Disease Control and Prevention, National Center for Injury Prevention and Control. Web-based injury statistics query and reporting system (WISQARS); 2005. Available at: www.cdc.gov/ncipc/wisqars. Accessed March 28, 2005
5. McClain PW, Sacks JJ, Froehlke RG, Ewigman BG. Estimates of fatal child abuse and neglect, United States, 1979 through 1988. *Pediatrics*. 1993;91:338–343
6. Caffey J. The whiplash shaken infant syndrome: manual shaking by the extremities with whiplash-induced intracranial and intraocular bleedings, linked with residual permanent brain damage and mental retardation. *Pediatrics*. 1974;54:396–403
7. Keenan HT, Runyan DK, Marshall SW, Nocera MA, Merten DF. A population-based comparison of clinical and outcome characteristics of young children with serious inflicted and noninflicted traumatic brain injury. *Pediatrics*. 2004;114:633–639
8. Kivlin JD, Simons KB, Lazowitz S, Ruttum MS. Shaken baby syndrome. *Ophthalmology*. 2000;107:1246–1254
9. Ewing-Cobbs L, Kramer L, Prasad M. Neuroimaging, physical, and developmental findings after inflicted and noninflicted traumatic brain injury in young children. *Pediatrics*. 1998;102:300–307
10. Duhaime AC, Alario AJ, Lewander WJ, et al. Head injury in very young children: mechanisms, injury types, and ophthalmologic findings in 100 hospitalized patients younger than 2 years of age. *Pediatrics*. 1992;90:179–185
11. Case ME, Graham MA, Handy TC, Jentzen JM, Monteleone JA, National Association of Medical Examiners Ad Hoc Committee on Shaken Baby Syndrome. Position paper on fatal abusive head injuries in infants and young children. *Am J Forensic Med Pathol*. 2001;22:112–122
12. Levin A. The ocular findings in child abuse. *Am Acad Ophthalmol*. 1998;16: 1–14
13. Tzioumi D, Oates R. Subdural hematomas in children under 2 years: accidental or inflicted? A 10-year experience. *Child Abuse Negl*. 1998;22:1105–1112
14. Kivlin J. A 12-year ophthalmologic experience with the shaken baby syndrome at a regional children's hospital. *Trans Am Ophthalmol Soc*. 1999;97:545–581
15. Pierre-Kahn V, Roche O, Dureau P, et al. Ophthalmologic findings in suspected child abuse victims with subdural hematomas. *Ophthalmology*. 2003;110:1718–1723
16. Greenwald MJ, Weiss A, Oesterle CS, Friendly DS. Traumatic retinoschisis in battered babies. *Ophthalmology*. 1986;93:618–625
17. Christian CW, Taylor AA, Hertle RW, Duhaime AC. Retinal hemorrhages caused by accidental household trauma. *J Pediatr*. 1999;135:125–127
18. Dashti SR, Decker DD, Razzaq A, Cohen AR. Current patterns of inflicted head injury in children. *Pediatr Neurosurg*. 1999;31:302–306
19. Johnson D, Braun D, Friendly D. Accidental head trauma and retinal hemorrhage. *Neurosurgery*. 1993;33:231–234
20. Elder J, Taylor R, Klug G. Retinal hemorrhage in accidental head trauma in childhood. *J Paediatr Child Health*. 1991;27:286–289
21. Buys YM, Levin AV, Enzenauer RW, et al. Retinal findings after head trauma in infants and young children. *Ophthalmology*. 1992;99:1718–1723
22. Levin A. Ophthalmology of shaken baby syndrome. *Neurosurg Clin Am*. 2002;13:201–211
23. Mierisch RF, Frasier LD, Braddock SR, Giangiacomo J, Berkenbosch JW. Retinal hemorrhages in an 8-year-old child: an uncommon presentation of abusive injury. *Pediatr Emerg Care*. 2004;20:118–120
24. Conradi S, Brissie R. Battered child syndrome in a four year old with previous diagnosis of Reye's syndrome. *Forensic Sci Int*. 1986;30:195–203
25. Hosokawa T, Hayasaka S, Yabata K, Tateda H. Two Japanese cases of battered child syndrome with retinal hemorrhage. *Ophthalmologica*. 1986;192:17–21
26. Pounder D. Shaken adult syndrome. *Am J Forensic Med Pathol*. 1997;18:321–324
27. Carrigan TD, Walker E, Barnes S. Domestic violence: the shaken adult syndrome. *Emerg Med J*. 2000;17:138–139
28. Massicotte S, Folberg R, Torczynski E, Gilliland MG, Luckenbach MW. Vitreoretinal traction and perimacular retinal folds in the eye of deliberately traumatized children. *Ophthalmology*. 1991;98:1124–1127

Findings in Older Children With Abusive Head Injury: Does Shaken-Child Syndrome Exist?

Hani Salehi-Had, James D. Brandt, Angela J. Rosas and Kristen K. Rogers

Pediatrics 2006;117:e1039-e1044

DOI: 10.1542/peds.2005-0811

Updated Information & Services	including high-resolution figures, can be found at: http://www.pediatrics.org/cgi/content/full/117/5/e1039
References	This article cites 24 articles, 6 of which you can access for free at: http://www.pediatrics.org/cgi/content/full/117/5/e1039#BIBL
Citations	This article has been cited by 1 HighWire-hosted articles: http://www.pediatrics.org/cgi/content/full/117/5/e1039#otherarticles
Subspecialty Collections	This article, along with others on similar topics, appears in the following collection(s): Office Practice http://www.pediatrics.org/cgi/collection/office_practice
Permissions & Licensing	Information about reproducing this article in parts (figures, tables) or in its entirety can be found online at: http://www.pediatrics.org/misc/Permissions.shtml
Reprints	Information about ordering reprints can be found online: http://www.pediatrics.org/misc/reprints.shtml

American Academy of Pediatrics

DEDICATED TO THE HEALTH OF ALL CHILDREN™

